

UCSC

Patient:) fernando
Address:
Phone:

Id number:

Gender: Male

Date of birth:

Indication :

A-Std <>

fernando

OD

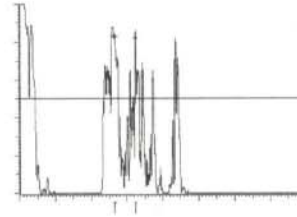
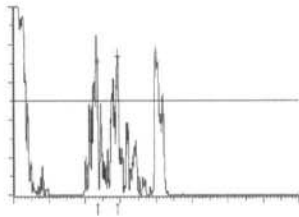
QM Aviso S V.4.0.0 - 19 mar 2019
T=93.6dB - Tumor Q-I

A-Std <>

fernando

OS

QM Aviso S V.4.0.0 - 19 mar 2019
T=93.6dB - Tumor Q-I



Velocity (m/s): 1550

Distance= 4.34mm

Quant-I (T)= 35%

AVG Height= 26%

Velocity (m/s): 1550

Distance= 4.46mm

Quant-I (T)= 40%

AVG Height= 33%

A-Std <>

fernando

OD

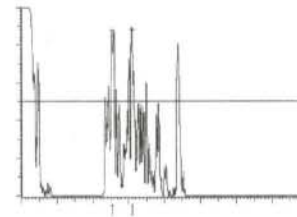
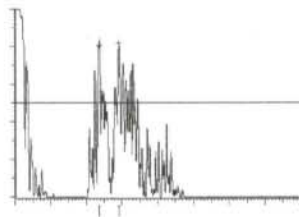
QM Aviso S V.4.0.0 - 19 mar 2019
T=93.6dB - Tumor Q-I

A-Std <>

fernando

OS

QM Aviso S V.4.0.0 - 19 mar 2019
T=93.6dB - Tumor Q-I



Velocity (m/s): 1550

Distance= 4.34mm

Quant-I (T)= 43%

AVG Height= 36%

Velocity (m/s): 1550

Distance= 4.34mm

Quant-I (T)= 48%

AVG Height= 36%

Ecografia Oftalmica

ID 9996
Data 19/03/2019
Cognome C
Nome Fernando
Eta 49
Anamnesi sospetta IHH

Referto

Ecografia Orbitaria OO: piano papillare non rilevato, regolare distribuzione del liquor negli spazi subaracnoidei periotici, il valore del diametro trasverso dei nervi ottici è nei limiti della norma bilateralmente OD 4.34mm, OS 4.46mm, utile perimetria computerizzata.

Dott.:

^

U

